

Total hip replacement in three cats: surgical technique, short-term outcome and comparison to femoral head ostectomy

W. D. Liska¹; N. Doyle¹; D. J. Marcellin-Little²; J. A. Osborne³

¹Gulf Coast Veterinary Specialists, Houston, Texas, USA; ²The Department of Clinical Sciences, College of Veterinary Medicine, North Carolina State University, Raleigh, North Carolina, USA; ³The Department of Statistics, College of Agriculture and Life Sciences, North Carolina State University, Raleigh, North Carolina, USA

Keywords

Cat, hip joint, total hip replacement, femoral head ostectomy

Summary

Objective: To describe the surgical technique and clinical features of total hip replacement (THR) due to hip trauma in cats.

Study design: Retrospective study.

Sample population: Three client-owned cats that underwent THR to treat capital epiphyseal fractures, and five client-owned cats that underwent femoral head ostectomy (FHO).

Methods: The clinical data included signalment, body weight, body condition score, diagnosis, implant size, surgical technique, intraoperative observations, and postoperative complications. Radiographic evaluation included implant positioning, cement mantle quality, and follow-up examination of the cement-bone interfaces. Orthopaedic examinations and client interviews were used to evaluate limb function.

Results: The three cats that underwent THR had a mean body weight of 5.5 kg, a mean body condition score of 6/9, and a mean age of three years at the time of surgery. The average THR follow-up was 11 months. For the five cats that underwent FHO, the mean body weight was 6.3 kg, mean body score was 7/9, and mean age at the time of FHO was 2.5 years. The average FHO follow-up was 22 months. Hip flexion, hip extension, and thigh girth after THR compared favourably to similar measurements made after FHO. The functional outcomes after THR were excellent. The functional outcomes after FHO ranged from poor to excellent.

Conclusion and clinical relevance: The recovery after THR was excellent based on clinical assessment of muscle mass, hip joint passive range of motion, gait, and owner assessment. Further blinded, randomised, and controlled trials of THR in cats are warranted.

performed to relieve pain in cats with OA or other chronic diseases of the hip joint that are non-responsive to medical management. However to our knowledge, very limited information regarding the clinical results of FHO in cats has been reported (5). Clinically, the results of FHO in cats appear somewhat unpredictable. It is not known if dorsal displacement of the femur or development of periarticular fibrosis after FHO in cats leads to morbidity from loss of hip extension and pain during extension.

Total hip replacement (THR) is widely used to manage hip disease in humans and dogs (6–8). Total hip replacement is primarily performed to eliminate pain and re-establish normal function in joints with non-septic OA when the pain is unresponsive to medical management. It is also performed to manage fractures that have a poor prognosis for successful surgical repair, coxofemoral luxations that cannot be maintained in reduction, avascular necrosis of the femoral head, and OA secondary to malunion of the pelvis or femur. Total hip replacement in dogs has been shown to effectively eliminate OA pain and lead to normal limb use as measured by force plate analysis (9–11). To our knowledge, reports that objectively document the degree of pain relief attained following FHO in cats based on force plate data or other computerised gait analysis systems are not available. Canine THR was historically performed on medium to giant dog breeds but its use has been recently expanded to include smaller patients weighing as little as 12 kg (12). Total hip replacement in the cat has been briefly mentioned in the literature (13). A recently introduced micro-THR system has been developed for use in small dog breeds and cats^a.

Correspondence to

Dr. William D. Liska
Gulf Coast Veterinary Specialists
1111 West Loop South 160
Houston, TX, 77027
USA
Phone: +1 713 693 1122
Fax: +1 713 693 1110
E-mail: DrLiska@GCVS.com

Vet Comp Orthop Traumatol 2009; 22: 505–510

doi:10.3415/Vcot-08-09-0087

Received: September 23, 2008

Accepted: July 20, 2009

Pre-published online: October 29, 2009

Introduction

Hip joint injuries and diseases in cats are common; these include fractures, luxations, and osteoarthritis (OA) secondary to hip dysplasia and previous trauma (1–3). The medical management of hip OA in cats presents

specific challenges because of their increased propensity to develop non-steroidal anti-inflammatory medication induced nephrotoxicity, as compared to dogs and humans, and also because of the inherent challenges in implementing specific exercise programs in cats (4). Femoral head ostectomy (FHO) may be

^a Micro Hip System: BioMedtrix, Boonton, NJ, USA

The purpose of this report is to describe the use and outcome of this micro-THR system in three cats.

Materials and methods

Animals

Cats that were presented after March 2006 for treatment of capital epiphyseal fractures were candidates for THR. Recorded data included age, gender, weight, and body condition score (14). One surgeon (WDL) performed all of the physical and orthopaedic examinations. Ventro-dorsal and lateral radiographs of the coxofemoral joints were obtained. Acetate templates of prosthetic stems and cups were overlaid on radiographs. The cranio-caudal acetabular length and the minimal medio-lateral endosteal femoral width were measured on the ventro-dorsal radiographic projection to ensure that the cats met the minimum size requirements for THR. A group of cats that had undergone FHO by the same surgeon for treatment of hip pain secondary to capital epiphyseal fracture, or coxofemoral luxation of less than 10 days duration were re-evaluated.

Total hip components and instrumentation

The modular cemented prosthesis system consisted of an ultra-high-molecular-weight polyethylene acetabular cup component, a chrome-cobalt femoral-stem component, and a femoral head^a (► Fig. 1). The cup and stem designs were scaled-down versions of cemented canine THR components^b. The cup instrumentation included 12-, 14-, and 16-mm-diameter power-driven, acetabular reamers and a cup inserter. The one-piece reamers had solid spiral cutting flutes. The stem instrumentation included a 13-cm-long awl for opening the femoral medullary canal after completion of a 45° femoral neck osteotomy (► Fig. 2), a fluted reamer to complete femoral bed preparation, and a stem inserter. Trial acetabular cups, femoral stems, and femoral heads were used to confirm implant fit.

^b CFX: BioMedtrix, Boonton, NJ, USA

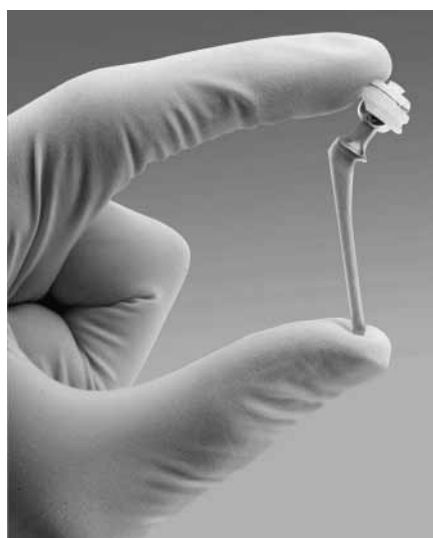


Fig. 1 The modular micro total hip replacement prosthesis includes an acetabular cup, femoral stem, and femoral head. The ultra-high-molecular-weight polyethylene acetabular cup component is available with a 12, 14, or 16 mm outside diameter with an 8 mm inside diameter articular surface. The cup has a dorsal truncation, concentric and radial grooves, and a stainless-steel wire for radiographic assessment of cup orientation. Two femoral stem sizes are available that measure 36 mm (# 2 with a 2.6-mm-diameter stem tip) or 46 mm (# 3 with a 3.6 mm diameter stem tip) in length. The stems have a 10 mm long, 4 mm diameter neck with a 2.86° Morse taper. The 8-mm-diameter femoral head is available with +0 or +2 mm neck length. (Printed with permission from BioMedtrix and W. D. Liska).

A femoral head impactor and tissue guard were also available.

Total hip replacement procedure

One surgeon (WDL) performed all of the procedures. The cats were premedicated with 0.1 mg/kg oxymorphone^c and 0.02 mg/kg glycopyrrolate^d administered intramuscularly. Anaesthesia was induced with 6.6 mg/kg propofol^e administered intravenously and maintained with an isoflurane-oxygen mixture throughout the procedure^f. After anaes-

^c Numorphan: Endo Pharmaceuticals, Chadds Ford, PA, USA

^d Baxter Healthcare Corp., Deerfield, IL, USA

^e Hospira, Lake Forest, IL, USA

^f AErrane: Baxter Healthcare Corp., Deerfield, IL, USA

thetic induction, a 12.5 µg/hr fentanyl patch^g was applied and left in place for five days. The same dose of oxymorphone was administered during anaesthetic recovery, and then every four to six hours afterwards for a total period of 12 to 24 hours. One milligram diazepam^h was administered intravenously if deemed necessary to calm the patient during recovery. Electrocardiogram, pulse oxymetry, capnography, and Doppler blood pressure were monitored throughout surgery. Lactated Ringer's solution was administered intravenously (20 mL/kg/hr for 2 hours, followed by 3 mL/kg/hr for 12 to 24 hours). Cefazolinⁱ (20 mg/kg every 6 hours for 18 hours) and gentamicin sulfate^j (3 mg / kg twice, 12 hours apart) were administered intravenously, starting 30 minutes before the skin incision.

The cranial lateral approach via a partial deep gluteal tenotomy and the surgical procedure were similar to that used for a conventional cemented THR (15, 16). Patient positioning was maintained using a 36 by 50 cm vacuum bean bag^k. Cup preparation included reaming using a 12 mm reamer, and making four or five holes into the exposed cancellous bone from the cranial to caudo-dorsal aspect of the acetabulum using a high speed burr^l. A trial cup was placed in the bone bed to assess depth of the preparation and optimal orientation based on its relationship to the cranial and caudal aspects of the acetabulum. Stem preparation included the use of the awl and the femoral reamer placed on a hand chuck. Trial acetabular and femoral implants were used to confirm proper implant sizing. Prior to cement implantation, the beds were copiously lavaged and packed with gauze for haemostasis. Two 20 g batches of polymethylmethacrylate^m (PMMA) were mixed with 1 g of cefazolin in vacuum mixing bowlsⁿ and were finger packed separately in dough phase into the acetabular bed and the femoral medullary canal, respectively.

^g Duragesic: Janssen Pharmaceutica Products, Titusville, NJ, USA

^h Valium: Baxter Healthcare Corp., Deerfield, IL, USA

ⁱ Apotex Corp., Wastin, FL, USA

^j Phoenix Scientific, St. Joseph, MO, USA

^k Vac-Hold Size 3: Olympic Medical, Seattle, WA, USA

^l Linvatec, Largo, FL, USA

^m Surgical Simplex P: Howmedica International, Limerick, Ireland

ⁿ Mixevac III: Stryker Orthopaedics, Mahwah, NJ, USA

The acetabular cup was implanted in the bed of PMMA with the cranial and caudal poles and dorsal truncation flush with the acetabular rim. The collar of the femoral stem was seated against and parallel to the femoral neck osteotomy. Prosthetic neck length was chosen to avoid laxity at the head cup interface. Stem tip centralizers or femoral canal cement restrictors were not used. Closure was routine. Ventro-dorsal and lateral radiographs of the coxofemoral joints were obtained immediately after surgery. The hip joints were extended and the femurs were positioned parallel to each other on the ventro-dorsal views. The hip joints were in a neutral position with the femurs slightly offset on the lateral view.

Total hip replacement postoperative management and assessment

Meloxicam^o was administered orally within 24 hours of surgery (0.2 mg/kg on day 1, 0.1 mg/kg on days two to five). Cefpodoxime proxetil^p (50 mg) was administered orally, once daily for four days starting 24 hours after surgery. The patients were discharged the day after surgery and the owners were instructed to prevent jumping and unsupervised activity; if necessary, confinement to a cage for six weeks afterwards was recommended. Rehabilitation exercises were not recommended. Functional progress and outcomes were assessed using physical examination and owners' interviews at the time of the last visit. Excellent outcome was assigned to cats able to sit, stand, walk normally and jump comfortably without the use of any analgesic medications. Good outcome was defined as any intermittent dysfunction: inability to sit, stand, walk or jump, or a perceived need for analgesics. A poor outcome was defined as daily evidence of dysfunction in these same parameters. A calibrated tape measure^q was used to measure mid-thigh girth at the final re-evaluation. A plastic goniometer^r was used to measure the passive range of motion

^o Boehringer Ingelheim Vetmedica, St. Joseph, MO, USA

^p Pfizer, New York, NY, USA

^q Gulick II: Country Technology, Gays Mills, WI, USA

^r Model 67079: Country Technology, Gays Mills, WI, USA

Fig. 2 A 13-cm-long awl (top) was used to open the femoral canal prior to reaming with a # 2/3 reamer on a hand chuck (bottom).

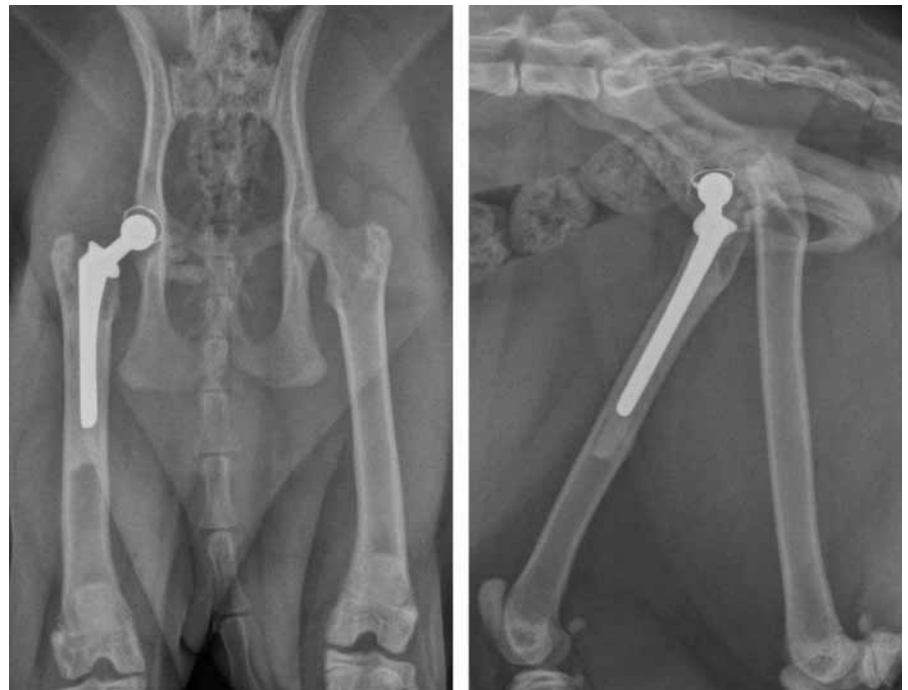


Fig. 3 Cranio-caudal and lateral radiographs of a cat made eight weeks after cemented total hip replacement. The femoral polymethylmethacrylate (PMMA) mantle is 1.0 to 1.5 mm thick. The PMMA fills the femoral canal for 6 mm distal to the stem tip. The thin PMMA mantle around the prosthetic cup is not clearly visible. Some PMMA inadvertently extruded on the caudo-ventral aspect of the acetabulum.

(PROM) of hip flexion and extension in the operated and contralateral limb that was tolerable to the non-sedated patient (17). Girth and goniometric measurements were made in triplicate by the same examiner (ND) who was unaware of the surgical procedures and operated sides.

Cranio-caudal and medio-lateral radiographs of the coxofemoral joints were made six weeks after surgery and at the end of the study. Stem and cup placement, stem sub-

sidence, periosteal and cortical bone changes, cement mantle integrity, and the presence of radiolucent lines were recorded at each time period and compared to each other. The dorsal displacement of the femur was measured by comparing the distance from the centre of the dorsal aspect of the acetabular rim to the proximal aspect of the greater trochanter on the operated and non-operated side on a lateral radiograph made with the hemipelvis superimposed. The presence of a stable cup

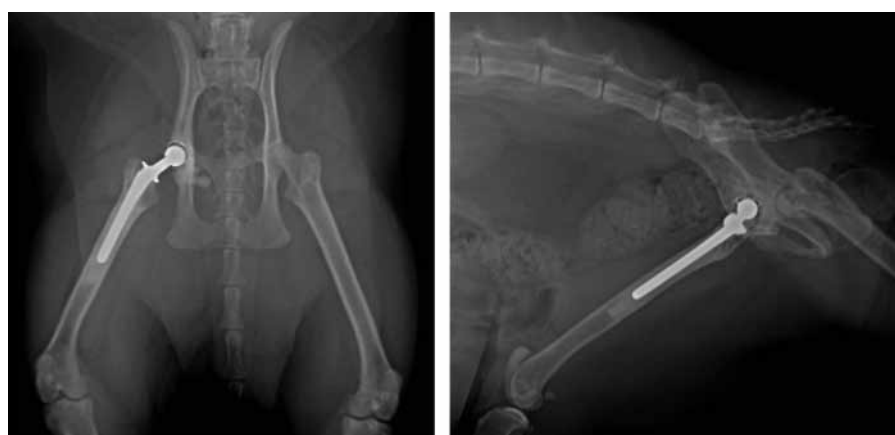

Fig. 4 Cranio-caudal and lateral radiographs of the cat in Figure 3 made 14 months after total hip replacement. Periosteal, cortical, or endosteal changes or radiolucent lines at the bone polymethylmethacrylate interfaces are not visible. The prosthetic cup and stem are stable.

and stem and the absence of complications were determined from these radiographs.

Femoral head ostectomy group

The postoperative management regimen after FHO was identical to the regimen of cats after THR with the exception of the absence

of confinement for cats after FHO. Instead, owners of cats with FHO were instructed to promote activity. The cats' owners were contacted and asked to bring their cats to the hospital for an examination. The functional assessments, measurements of thigh girth, PROM hip flexion and extension, and radiographs of cats with FHO were performed once, at the study's endpoint.

Table 1 Selected clinical and radiographic features in cats after total hip replacement or femoral head ostectomy.

	Total hip replacement	Femoral head ostectomy
Thigh circumference* (cm)		
● Operated limb†	21.7 ± 3.4 (98%)	19.7 ± 1.6 (92%)
● Non-surgical limb	22.1 ± 4.2	22.2 ± 1.7
Hip flexion (°)		
● Operated limb†	29 ± 10 (98%)	32 ± 3 (103%)
● Non-surgical limb	30 ± 9	31 ± 5
Hip extension (°)		
● Operated limb†	148 ± 1 (98%)	138 ± 8 (96%)
● Non-surgical limb	151 ± 8	144 ± 7
Dorsal femoral displacement (mm)	0 ± 0	11 ± 3

Key: * = mean ± standard deviation of three total hip replacements in three cats and six femoral head ostectomies in five cats; † = absolute values and percentages of mean non-surgical limb values.

Results

Total hip replacement was performed in three cats with capital physal fractures; two were spayed females and one was a neutered male. The cats were presented with weight-bearing lameness with a mean duration of 10 days. A severe pain response to hip extension was initially present. One cat with a femoral head non-union had two prior surgeries before the THR procedure: surgery was performed on the operated limb to repair a supracondylar femoral fracture five years previously, and also an intertarsal luxation six weeks prior. Mean age was 37 months (17, 20, and 74 months), mean weight was 5.6 kg (3.7, 5.5, and 7.7 kg), and mean body condition score was six (4, 6, and 8).

The THR procedure for cats closely resembled the THR procedure as performed in dogs, but used smaller periosteal elevators and retractors. Mean duration of surgery was 96 minutes (range, 90 to 102 minutes). The implants used in the cats were a 12 mm cup, a #-3 stem, and a +2 head (n = 2) or a +0 head (n = 1). Based on postoperative radiographic examination, cup and stem orientation were deemed appropriate (►Fig. 3). The acetabular and femoral cement mantles were 1- to 2-mm-thick. Some PMMA had extruded on the caudo-ventral aspect of the acetabulum in one cat, however the cat did not have any neurological compromise. One cat had laxity of the ipsilateral patella noted at surgery that progressed to a medial patellar luxation; this was surgically stabilised three weeks after THR surgery. One cat jumped on a kitchen counter three days after surgery, without negative consequences. This event provided impetus to recommend confinement for six weeks to an area where jumping onto objects higher than 25 cm was prevented. The mean THR clinical and radiographic follow-up time was 11 months (range: 9 to 14 months; ►Fig. 4). Functional outcome was excellent for all three cats. Clinical measurements are reported in ►Table 1. The hip joints were pain-free and had a normal feel (end feel) in maximal passive flexion and extension (18). The prosthetic cups and stems were considered stable and were without any radiolucent lines apparent at the bone-cement interfaces.

Fifteen cats that had previously undergone FHO were identified. Ten of these cats were dead or lost to follow-up. Five cats with six FHO were re-evaluated. Mean age at sur-

ger was 28 months (range: 6 to 58 months), mean weight was 6.3 kg (range: 3.2 to 8.3 kg), and mean body condition score was seven (range: 5 to 8). The indications for FHO surgery were capital epiphyseal fracture ($n = 4$) and coxofemoral luxation ($n = 2$). The mean FHO clinical and radiographic follow-up time was 22 months (range: 8 to 39 months). The functional outcomes after FHO were excellent for two cats and poor for three cats. Three of the five cats strongly resisted full hip extension. One cat was fractious, necessitating that measurements be taken under anaesthesia, thus patient tolerance of PROM hip extension could not be assessed.

Discussion

This study included all cats that received a THR, with approximately one year of follow-up. Our control group included all cats that underwent FHO and received follow-up for one year or more. This study had several limitations. It included a small number of patients that were followed for a relatively brief postoperative period. It is, nevertheless, the first report of THR in client-owned cats, to our knowledge.

Use of an awl allowed a safe and precisely centred opening in the femoral canal. In our opinion, reaming the femoral canal using the awl and reamer by hand on a chuck rather than a power drill lowered the likelihood of cortical penetration, fissures, or fractures and optimised stem orientation.

The PMMA was placed in dough phase rather than liquid phase for the cats in this report. While low viscosity PMMA implantation and pressurisation are beneficial in humans compared to high viscosity implantation, the benefits in smaller patients are not known (19). Because the flow of low viscosity cement follows the path of least resistance, it may be beneficial to use a cement restrictor plug when implanting a stem using low viscosity cement. However, PMMA or polyethylene restrictor plugs for cats and miniature dogs are not commercially available. A cement restrictor plug could be made by collecting a small amount of PMMA from the batch mixed for cup implantation and injecting it into the femoral canal, making sure that it is placed several millimetres distal to the stem tip. The bone implant interfaces were stable in all patients during the first

postoperative year, despite the presence of thin PMMA mantles compared to the mantles generally achieved in dogs. While the long-term impact of thin PMMA mantles in cats is not known, thin mantles have been reported to be successful in humans. Aseptic loosening was present in only six of 964 people with thin cement mantles 24 years after surgery (20). In dogs, we have had a long-term failure rate of less than five percent of the bone PMMA interfaces in more than 800 cemented canine THR that were placed with relatively thin cement mantles (21). Our low complication rate may be due to meticulous attention to cleaning and drying the bone bed before PMMA placement and to having proper stem orientation (22). We also believe that intrusion of cement into cancellous bone is important in order to create a bone-cement interface that will withstand forces applied over the long-term (23). Thin PMMA mantles have also been recommended by some surgeons when performing hip resurfacing to decrease the likelihood of thermal bone necrosis that could potentially result from thick mantles (24). The significance of the effect of thermal necrosis on thin bone in small patients, including cats, has not been reported to our knowledge. Although extrusion of PMMA has been suggested to be a cause of sciatic neuropathy in dogs, this complication was not encountered in any of the three cats (25). However, a study of 1000 consecutive THR procedures in dogs with a total of 19 sciatic neurapraxia complications demonstrated that the exothermic reaction of PMMA did not create the complication in any of the cases (26). Polymethylmethacrylate extrusion or the formation of a granuloma associated with THR could also lead to tenesmus (27). While we did not detect signs of aseptic loosening in the THR in our study, it is important to note that the signs of aseptic loosening may be difficult to detect on plain radiographs (28, 29).

The confinement and postoperative rehabilitation of cats after THR presents different challenges compared to confinement and rehabilitation of dogs after THR. Cats tend to be more independent than dogs. In our opinion, owner compliance in implementing confinement in the early postoperative period is important, particularly to restrict patients' tendencies to jump. While we recommend leash walks during the recovery of dogs, we do not recommend an exercise program for cats after THR due to their high self-selected activity

level. The results of our small study suggest that it may be safe to allow cats to resume free activity after six weeks of confinement.

The patellar laxity detected in one of our cases may have been present before surgery, or it may have resulted from changes in the *quadriceps femoris* muscle tension or limb geometry due to THR. A +0 mm femoral head was used in that patient. Patellar luxation could conceivably result from a THR with a prosthetic neck that is too long or too short. A long neck could increase the femoral shaft offset and rectus femoris tension, whereas a short neck could lead to laxity of the rectus femoris. Patellar luxations have also been reported after FHO. In one report, patellar luxation was present in 18% of dogs after FHO, predominantly in the contralateral, nonsurgical pelvic limb (30). A weak relationship has been reported between patellar luxation and hip dysplasia in cats (31).

The functional and physical results of the THR performed in this study were excellent and compared favourably to the results of our FHO, based on the absence of pain response to palpation (lack of patient objection), on symmetry of thigh girth between operated and opposite limbs, on the absence of dorsal displacement of the greater trochanter in relation to the pelvis, and on the functional outcomes reported by the owners. The dropout rate for FHO patients in this study was high (66%) and could have introduced a bias in the study. While the impact of this high dropout rate on the results of this study is not known, it would appear unlikely that patients that did well after FHO were more likely to drop out than patients that did poorly. The high dropout rate of FHO patients and resulting small sample size would have negatively affected our ability to detect statistical differences between patient groups. We therefore decided to avoid statistical comparisons in this report.

The data summarised in this report suggests that hip joint extension and thigh girth could be equal or larger after THR compared to FHO. The response of hip joint flexion to surgery was seemingly more complex. This possibly resulted from the fact that hip joint flexion could be increased in patients with thinner joint capsules and less periarticular fibrosis (e.g. THR patients) compared to patients with thicker joint capsules and more periarticular fibrosis (e.g. FHO patients), but flexion could be increased in patients with

smaller thigh muscle mass (e.g. FHO patients) compared to patients with larger thigh muscle mass (e.g. THR patients).

The successful outcomes of THR in this report are in agreement with a report of 83% good or excellent outcomes for 17 small dogs weighing from 12 to 25 kg and followed for four to 42 months (mean follow-up, 17 months) (12). The FHO procedures, by comparison, led to a dorsal displacement of the greater trochanter, pain on hip extension, a deficit in thigh muscle mass, and to variably successful long-term functional outcomes. The variable success after FHO for cats in this report is in agreement with previous reports involving cats, small dogs, and large dogs (5, 30, 32, 33). The mean dorsal femoral displacement in this report (11 mm) was similar to the mean dorsal displacement (14 mm) that was present in 43 of 62 dogs after FHO (30). A mean (\pm SD) loss of limb length of $2.0 \pm 0.9\%$ was reported in eight dogs that underwent standard FHO (33). Bilateral FHO has been reported in a group of 15 dogs (34). The owners of these dogs reported good to excellent limb use. Early physiotherapy has been recommended after FHO (34). The implementation of early physiotherapy for the cats in this study could have possibly influenced the long-term outcome of the procedures. The relative long-term benefits of THR and FHO in cats with regards to perceived pain, limb use, thigh girth, and hip joint motion cannot be determined from this report, but would be ideally determined through a prospective clinical trial including a pressure-sensitive walkway (35). While prospective trials comparing THR and FHO are not available in dogs, weight-bearing as measured on a force plate, returns to normal values after THR, but not after FHO (9, 11, 36). Total hip replacement may represent an attractive alternative to FHO for cats with hip joint problems that cannot be successfully managed medically. The patients in this report had short-term pathology and normal acetabular and femoral anatomy. Total hip replacement may be more challenging in cats with long-term pathology with abnormal anatomy, loss of bone stock, or periarticular fibrosis.

This report does not provide any evidence of any detrimental effect of the THR procedure when compared with FHO with regard to the outcomes of hip flexion, hip extension, and thigh girth. We concluded from this report that THR may be a viable surgical option in cats. Further investigation of this

procedure using a blinded randomised controlled trial is warranted.

Acknowledgements

No outside funding was received for this study.

References

- Hardie EM, Roe SC, Martin FR. Radiographic evidence of degenerative joint disease in geriatric cats: 100 cases (1994–1997). *J Am Vet Med Assoc* 2002; 220: 628–632.
- Fischer HR, Norton J, Kobluk CN, et al. Surgical reduction and stabilization for repair of femoral capital physal fractures in cats: 13 cases (1998–2002). *J Am Vet Med Assoc* 2004; 224: 1478–1482.
- Kawamata T, Niiyama M, Taniyama H. Open reduction and stabilisation of coxofemoral joint luxation in dogs and cats, using a stainless steel rope inserted via a ventral approach to the hip joint. *Aust Vet J* 1996; 74: 460–464.
- Parton K, Balmer TV, Boyle J, et al. The pharmacokinetics and effects of intravenously administered carprofen and salicylate on gastrointestinal mucosa and selected biochemical measurements in healthy cats. *J Vet Pharmacol Ther* 2000; 23: 73–79.
- Gendreau C, Cawley AJ. Excision of the femoral head and neck: the long term results of 35 operations. *J Am Anim Hosp Assoc* 1977; 13: 605–608.
- Eingartner C. Current trends in total hip arthroplasty. *Ortop Traumatol Rehabil* 2007; 9: 8–14.
- Olmstead ML. Canine cemented total hip replacements: state of the art. *J Small Anim Pract* 1995; 36: 395–399.
- Marcellin-Little DJ, DeYoung BA, Doyens DH, et al. Canine uncemented porous-coated anatomic total hip arthroplasty: results of a long-term prospective evaluation of 50 consecutive cases. *Vet Surg* 1999; 28: 10–20.
- Anderson GI, Hearn T, Taves C. Force plate gait analysis in normal and dysplastic dogs before and after total hip replacement surgery: an experimental study. *Vet Surg* 1988; 17: 27.
- Dogan S, Manley PA, Vanderby R Jr, et al. Canine intersegmental hip joint forces and moments before and after cemented total hip replacement. *J Biomech* 1991; 24: 397–407.
- Budberg SC, Chambers JN, Lue SL, et al. Prospective evaluation of ground reaction forces in dogs undergoing unilateral total hip replacement. *Am J Vet Res* 1996; 57: 1781–1785.
- Warnock JJ, Dyce J, Pooya H, et al. Retrospective analysis of canine miniature total hip prostheses. *Vet Surg* 2003; 32: 285–291.
- Nunamaker DM. Textbook of small animal orthopaedics. In: Newton CD, Nunamaker DM, editors. Philadelphia: J.B. Lippincott Company, 1985; 555–560.
- Laflamme D. Development and Validation of a Body Condition Score System for Cats: A Clinical Tool. *Feline Pract* 1997; 25: 13–18.
- Brown SG, Rosen H. Craniolateral approach to the canine hip: a modified Watson-Jones approach. *J Am Vet Med Assoc* 1971; 159: 1117–1122.
- Olmstead ML. The canine cemented modular total hip prosthesis. *J Am Anim Hosp Assoc* 1995; 31: 109–124.
- Jaeger GH, Marcellin-Little DJ, Depuy V, et al. Validity of goniometric joint measurements in cats. *Am J Vet Res* 2007; 68: 822–826.
- Levine D, Millis DL, Marcellin-Little DJ. Introduction to veterinary physical rehabilitation. *Vet Clin North Am Small Anim Pract* 2005; 35: 1247–1254.
- Dunne NJ, Orr JF. Flow characteristics of curing polymethyl methacrylate bone cement. *Proc Inst Mech Eng [H]* 1998; 212: 199–207.
- Cameron HU. Cemented Femoral Fixation: Thin Mantles, The French Paradox. *Sem Arthroplasty* 2008; 19: 144–147.
- Liska WD. Femur fractures associated with canine total hip replacement. *Vet Surg* 2004; 33: 164–172.
- Lidgren L, Robertson O. Acrylic bone cements: clinical developments and current status. *Scandinavia. Orthop Clin North Am* 2005; 36: 55–61.
- Lucksanasomboon P, Higgs WA, Ignat M, et al. Comparison of failure characteristics of a range of cancellous bone-bone cement composites. *J Biomed Mater Res A* 2003; 64: 93–104.
- Little JP, Gray HA, Murray DW, et al. Thermal effects of cement mantle thickness for hip resurfacing. *J Arthroplasty* 2008; 23: 454–458.
- Massat BJ, Vasseur PB. Clinical and radiographic results of total hip arthroplasty in dogs: 96 cases (1986–1992). *J Am Vet Med Assoc* 1994; 205: 448–454.
- Andrews CM, Liska WD, Roberts DJ. Sciatic neuropathia as a complication in 1000 consecutive canine total hip replacements. *Vet Surg* 2008; 37: 254–262.
- Freeman CB, Adin CA, Lewis DD, et al. Intrapelvic granuloma formation six years after total hip arthroplasty in a dog. *J Am Vet Med Assoc* 2003; 223: 1446–1449, 1433.
- Edwards MR, Egger EL, Schwarz PD. Aseptic loosening of the femoral implant after cemented total hip arthroplasty in dogs: 11 cases in 10 dogs (1991–1995). *J Am Vet Med Assoc* 1997; 211: 580–586.
- Frankel DJ, Pluhar GE, Skurla CP, et al. Radiographic evaluation of mechanically tested cemented total hip arthroplasty femoral components retrieved postmortem. *Vet Comp Orthop Traumatol* 2004; 17: 216–224.
- Duff R, Campbell JR. Long term results of excision arthroplasty of the canine hip. *Vet Rec* 1977; 101: 181–184.
- Smith GK, Langenbach A, Green PA, et al. Evaluation of the association between medial patellar luxation and hip dysplasia in cats. *J Am Vet Med Assoc* 1999; 215: 40–45.
- Duff R, Campbell JR. Effects of experimental excision arthroplasty of the hip joint. *Res Vet Sci* 1978; 24: 174–181.
- Mann FA, Tangner CH, Wagner-Mann C, et al. A comparison of standard femoral head and neck excision and femoral head and neck excision using a biceps femoris muscle flap in the dog. *Vet Surg* 1987; 16: 223–230.
- Rawson EA, Aronsohn MG, Burk RL. Simultaneous bilateral femoral head and neck ostectomy for the treatment of canine hip dysplasia. *J Am Anim Hosp Assoc* 2005; 41: 166–170.
- Lascelles BD, Findley K, Correa M, et al. Kinetic evaluation of normal walking and jumping in cats, using a pressure-sensitive walkway. *Vet Rec* 2007; 160: 512–516.
- Planté J, Dupuis J, Beaugard G, et al. Long-term results of conservative treatment, excision arthroplasty and triple pelvic osteotomy for the treatment of hip dysplasia in the immature dog. Part 2: Analysis of the ground reaction forces. *Vet Comp Orthop Traumatol* 1997; 10: 130–135.